



ELSEVIER



## CASE REPORTS

# Complications of polyalkylimide 4% injections (Bio-Alcamid™): a report of 18 cases

R.B. Karim <sup>a,\*</sup>, J.J. Hage <sup>b</sup>, L. van Rozelaar <sup>c</sup>, C.A.H. Lange <sup>d</sup>,  
J. Raaijmakers <sup>a</sup>

<sup>a</sup> Department of Plastic and Reconstructive Surgery, Onze Lieve Vrouwe Hospital, P.O. Box 95500, 1090 HM Amsterdam, The Netherlands

<sup>b</sup> Department of Plastic and Reconstructive Surgery, Antoni van Leeuwenhoek Hospital, Plesmanlaan 121, 1066 CX Amsterdam, The Netherlands

<sup>c</sup> Medical Laser Centre, J. van Goyenkade 2, 1075 HN Amsterdam, The Netherlands

<sup>d</sup> Department of Radiology, Onze Lieve Vrouwe Hospital, P.O. Box 95500, 1090 HM Amsterdam, The Netherlands

Received 14 March 2005; accepted 1 January 2006

### KEYWORDS

Bio-Alcamid™;  
Complications;  
Cosmetic;  
Aesthetic;  
Filler

**Summary** Injectable filler materials can be valuable to aesthetic surgeons. To date, hardly any short-term and no long-term complications of polyalkylimide injections (Bio-Alcamid™) have been reported. We present and discuss the history of 18 patients who had such complications.

The patients were between 31 and 55 years of age. The time between injection and the onset of complications of polyalkylimide ranged from 1 month to 3 years. Additional invasive therapy at, or near, the site of injections triggered the onset of infection in 10 patients. By use of T2-weighted MRI with fat suppressing spectro-presaturation inversion recovery (SPIR) the filler material can be visualised. Once infection or migration of the permanent filler occurs, the therapeutic options are limited to surgical removal by a direct approach.

Polyalkylimide should be handled under strict antiseptic circumstances. This does not only apply at the time of initial injections, but even more during any subsequent invasive treatment such as evacuation of surplus deposits or additional surgical procedures at, or near, the site of injection.

© 2006 The British Association of Plastic Surgeons. Published by Elsevier Ltd. All rights reserved.

\* Corresponding author. Tel.: +31 20 599 2543; fax: +31 20 599 2544.

E-mail address: r.b.karim@olvg.nl (R.B. Karim).

From the onset of the 20th Century onward, medical attempts to smoothen or decrease facial wrinkles and lines have been made.<sup>1</sup> The means vary from purely surgical treatment (e.g. facelifts

and dermal autografts) to a fully pharmacological or physical resurfacing therapy (e.g. trichloroacetic acids and laser).<sup>1,2</sup> In the second half of the past century, injectable therapeutic options gained popularity. These 'injectables' can be divided into two main groups. First there are injectable pharmaceuticals such as botulin toxin type A. The second group of injectables can be described as 'filler materials'.<sup>3,4</sup> Just like dermal autografts and synthetic implants, these liquid fillers are meant to substitute the lost subcutaneous skin supporting tissues and, hence, reduce wrinkles in a physical way. Three different categories of injectable filler materials may be distinguished (Table 1). First, there are biodegradable fillers such as plain hyaluronic acid and bovine collagen that are effective for up to a few months.<sup>5,6</sup> Second, there are semi-permanent fillers such as lactate acid and cross-linked hyaluronic acid that are effective from a few months up to a year and,<sup>6</sup> finally, there are permanent fillers such as polyalkylimide and polyacrylamide that are meant to last *in situ* for many years.<sup>7,8</sup>

Because biodegradable fillers are only temporarily effective, their use is supposedly safe and predictable in the hands of experienced medical

professionals.<sup>3,9</sup> The most common complication of these short-term fillers is an allergic reaction that may be prevented by an adequately performed screening. Once it occurs, this complication may simply be managed by patience. Coping with complications that arise after the use of semi-permanent or permanent filler materials is more demanding. The most common complications of such fillers are low-grade infections, granuloma, and spread of the filler from the treated area to the adjacent regions and tissues.<sup>3,10,11</sup>

Since 2001, polyalkylimide 4% (Bio-Alcamid™, Polymekon, Milan, Italy) is used as a permanent filler in the Netherlands.<sup>7</sup> To date, hardly any short-term, and no long-term complications of this permanent filler have been reported.<sup>12,13</sup> We present the case history of a patient who suffered two of the most common complications and a summary of 17 additional cases to stress that the complications can lead to the opposite of the aesthetic result that was obtained initially. Because adverse reactions are alleged not to occur later than 1 year after injection,<sup>13</sup> we made a distinction between patients who suffered a complication within the first year after injection, and those who presented after more than 1 year.

**Table 1** Injectable filler materials currently available commercially in the Netherlands

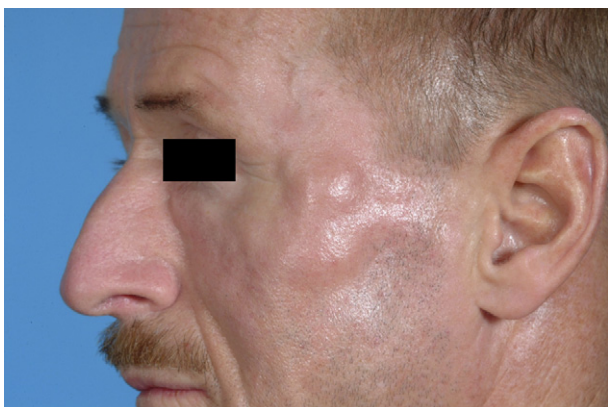Longevity	Name	Filler component	Term of effect	Producer
Short-term	Hylaform	Cross-linked rooster comb hyaluronic acid	2–4 months	Biomatrix
	Juvelift IHL	Non-cross-linked bacterial hyaluronic acid	1–3 months	Leaderm
Medium-term	Rofilan	Hyaluronic acid	2–5 months	Rofil
	Bioinblue	Polyvinyl alcohol 8%	10–14 months	Polymekon
	Juvederm HV	Cross-linked bacterial hyaluronic acid	6–13 months	Leaderm
	New fill	Polylactate acid	12–24 months	Aventis
	Restylane	Cross-linked synthetic hyaluronic acid	5–12 months	Q-Med
	Perlane	Cross-linked synthetic hyaluronic acid	8–12 months	Q-Med
Long-term	Reviderm intra	Sephadextran + hyaluronic acid	4–12 months	Rofil
	Zyderm	Bovine skin collagen	6–8 months	Inamed
	Zyplast	Collagen and glutaraldehyde cross-linked	6–8 months	Inamed
	Artecoll	Polymethylmethacrylate + bovine collagen	Semi-permanent	Rofil
	Dermalive	Hyaluronic acid + acrylhydrogel	Semi-permanent	J.S.C.
	Bio-Alcamid	Polyalkylimide 4%	Permanent	Polymekon
	Biopolymer	Polymethylsiloxane (silicone)	Permanent	Silskin
	PMS	Polymethylsiloxane (silicone)	Permanent	Bausch&Lomb
	Silicone oil	Polymethylsiloxane (silicone)	Permanent	Alcon Labs

## Case report

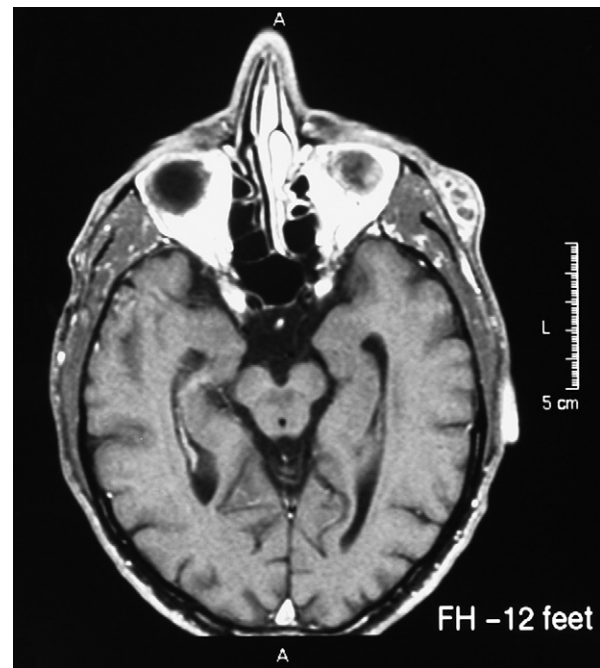
A 55-year-old man had been treated for severe facial lipodystrophy resulting from highly active anti-retroviral therapy (HAART) medication.<sup>14,15</sup> During multiple sessions, the loss of subcutaneous fatty tissue had been compensated by injections of polyalkylimide 4%.<sup>12</sup> The post-treatment course had been uneventful and the patient had initially been satisfied with the result of this treatment. Two years later, the patient underwent a partial evacuation of some polyalkylimide at the left temporal area where the depot was bulging too much. A few weeks after this evacuation, he presented with a redness and swelling of the area. All subsequent antibiotic therapies led to temporary relief of these symptoms. Over time, the area surrounding the evacuation site became hard and painful on touch (Fig. 1). Magnetic resonance imaging (MRI) revealed a small amount of filler material at the left temporal area to be involved in an inflammatory process (Fig. 2). Additionally, a small, non-painful, non-red, swelling was present in the nasal corner of the right upper eyelid where the patient claimed to have never received any injections. A localised festering mass with no macroscopic remnants of filler material was surgically removed from the left side of the head (Fig. 3). Histologically, the specimen showed double-breaking material and foreign body reaction (Fig. 4). A small incision over the swelling in the eyelid yielded approximately 0.25 ml of filler material.

## Summary of additional cases

We saw 17 additional patients who had polyalkylimide 4% injections and observed some similarities

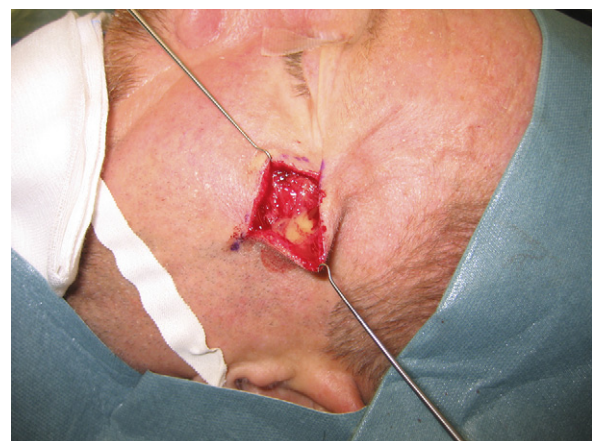

**Figure 1** Painful, indurated left temporal area following partial evacuation of polyalkylimide filler material, some 2 years after initial injection in a 55-year-old man.

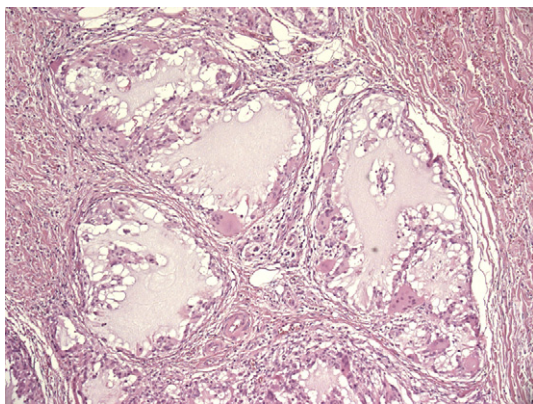


**Figure 2** After intravenous injection of gadolinium DTPA, T1-weighted MRI revealed a small amount of polyalkylimide in the left temporal area to be involved in the inflammatory process in the same patient.

among the course of complications in these and our first patient (Table 2). HIV-positive patients typically present late in their fifth, or early in their sixth decade, whereas cosmetic patients presented with facial wrinkles in their fourth decade.<sup>9</sup> Additional invasive therapy at, or near, the site of injections had triggered the onset of infection in seven of the additional seventeen patients seen with this complication. These therapies included additional injection of filler material ( $n=2$ ),



**Figure 3** A localised festering mass with no macroscopic remnants of polyalkylimide was surgically removed from this indurated area.



**Figure 4** Histological examination of the surgical specimen revealed foreign body reaction of histiocytes surrounding a double-breaking material supposed to be polyalkylimide (haematoxylin and eosin stain).

blepharoplasty ( $n = 1$ ) or other invasive treatment ( $n = 2$ ), and dental treatment ( $n = 2$ ).

In all, eight patients presented because of infection of the filler material and five because of capsular contraction. Migration of the injected material was the primary reason for presentation in the five remaining patients even though it was observed in 12 of all 18 patients. Overall, more than one type of complication was observed in eight patients. The lag of time between injection

and the onset of complications of polyalkylimide ranged from 1 month to 3 years (mean, 15 months). This time lag ranged from 1 to 12 months (mean, 6 months) in the 11 patients presenting for short-term complications, and from 2 to 3 years (mean, 28 months) in the seven patients presenting for long-term complications. MRI examination was performed in 16 patients, using T2-weighted sequence with fat suppressing spectro-presaturation inversion recovery (SPIR) to visualise the filler material. Additionally, we performed T1-weighted pulse sequences after intravenous injection of the paramagnetic contrast medium gadolinium DTPA to objectify possible abscesses or phlegmonous inflammation. To date, seven patients underwent surgical removal of polyalkylimide and the material was evacuated by puncture in two additional patients.

## Discussion

Polyalkylimide is one of the subtypes of polyacrylamide gel (PAAG) that consists of a minor backbone of 2.5 to 5% cross-linked polyacrylamide and 95 to 97.5% water. These water molecules supposedly are highly exchangeable with the water molecules of the human tissue fluid, which may

**Table 2** Characteristics of 18 patients presenting with complications of polyalkylimide injections

Sex	Age	Indication	Time lag	Complication	Co-complication	Diagnosis	Therapy
M <sup>a</sup>	55	Lipodystrophy	>1 year	Infection	Migration	MRI	Surgery
M	54	Rejuvenation	>1 year	Infection	None	MRI	Surgery
F	55	Rejuvenation	>1 year	Migration	None	MRI	Surgery
F	45	Rejuvenation	>1 year	Capsule	Migration	MRI	None so far
F	53	Rejuvenation	>1 year	Infection	Migration/ Capsule	US	Antibiotics
M	52	Lipodystrophy	>1 year	Migration	None	MRI	None so far
F	41	Rejuvenation	>1 year	Infection	None	MRI	Evacuation
M	47	Lipodystrophy	≤1 year	Infection	Migration	MRI	Antibiotics
M	46	Lipodystrophy	≤1 year	Capsule	None	—	None so far
M	43	Lipodystrophy	≤1 year	Capsule	None	MRI	None so far
M	44	Lipodystrophy	≤1 year	Infection	Migration/ capsule	MRI	Surgery
M	39	Rejuvenation	≤1 year	Infection	Migration	MRI	Surgery
F	31	Rejuvenation	≤1 year	Capsule	Migration	MRI	Surgery
M	37	Rejuvenation	≤1 year	Infection	Capsule	MRI	Antibiotics
F	36	Rejuvenation	≤1 years	Migration	None	MRI	None so far
F	53	Rejuvenation	≤1 years	Capsule	None	MRI	Surgery
F	40	Rejuvenation	≤1 year	Migration	None	MRI	None so far
F	51	Rejuvenation	≤1 year	Migration	None	MRI	Evacuation

Age: age at presentation with the complication of polyalkylimide; Indication: indication of initial polyalkylimide injections; Time lag: time period between injection and onset of complication of polyalkylimide; MRI: magnetic resonance imaging; US: ultrasonography.

<sup>a</sup> The history of this patient is described in more detail in the [Case report](#).

reduce or prevent the settlement of biofilm and thus hinder the low-grade, long-term infection associated with other filler materials.<sup>13</sup> The foreign body response to PAAGs is alleged to reduce with time and to end up in a low-grade host response at 6 months or no response at all at 2 years. Christensen et al.<sup>13</sup> felt that the hydrophilic character of PAAGs explained why they and Protópapa et al.<sup>12</sup> observed no adverse reactions later than 1 year after injection. Contrary to these authors, we observed complications with an onset at 2 years after injection in seven of our patients. These long-term complications were associated with additional invasive treatment more often than short-term complications (5 out of 7 versus 5 out of 11). Short-term complications may be associated more often with an inadequate technique of injection of the filler.

Polyalkylimide 4% is to be viewed as an injectable liquid endoprosthesis.<sup>3,7</sup> Hence, it is prone to the potential drawbacks of an endoprosthesis such as excessive capsule formation, dislocation or migration, and infection. Consequently, the prevention, diagnosis and therapy of these complications are very similar to those of complications of other implants, e.g. breast implants. Handling the filler under strict antiseptic circumstances may prevent infection. This does not only apply at the time of initial injections, but even more during any subsequent invasive treatment at, or near, the site of injection such as evacuation of surplus depots or additional surgical procedures. Migration and capsule formation are harder to prevent. As holds true for breast implants, injected polyalkylimide induces fibroblast proliferation and capsule formation. The severity of the capsule formation is unpredictable and varies between patients. Excessive capsule formation may not be prevented, as it is probably rather a patient-dependent entity than a filler-specific side effect. Capsular contraction will change the shape of the injected polyalkylimide depot to a sphere. The filler mass thus compressed feels unnaturally hard to touch and may severely diminish the cosmetic effect initially achieved by the injection.

The polyalkylimide depots may well be visualised by a heterogeneously increased signal on T2-weighted MRI using fat suppression (SPIR). Plain radiography and CT-scanning are of no diagnostic value to objectify the filler material as the cause for capsular problems, migration, or infection in these cases. Although ultrasonography is a valuable substitution for patients who cannot or will not undergo MRI, the differentiating power of ultrasonography is less and the specificity is lower in comparison with MRI.

Capsule formation is an unusual reason for the patient to undergo evacuation of the filler material. Such evacuation may easily be achieved by puncturing the capsule with a large gauge needle to squeeze the filler gel out, provided this material has not lost coherence by diffuse migration. Contrary to what its manufacturer claims, smaller amounts of the injected filler may not easily be removed by such puncturing and squeezing and, consequently, surgery may well be needed to remove all the injected material after migration. When performing such surgery, the shortest route to the injected material should be taken in order to prevent contamination and infection of any remaining material and the tissues surrounding it.

Infection of a permanent filler is a more serious complication as infected foreign material can hardly ever be sufficiently treated medically. Systemic or intra-lesional application of corticosteroids and antibiotics may temporarily relieve the symptoms of infection but will not cure it.<sup>3,16,17</sup> Sometimes, injections of 5-fluoro-uracil are even being tried to treat such inflammation but this is highly controversial as its therapeutic value in these cases has not been proven and also it holds the risk of destruction of draining lymph-vessels. In cases where infection has occurred, more often than not, the foreign material has to be removed surgically to adequately treat the infection.<sup>9,16,17</sup> Depending on the site where the material was deposited and the final localisation of the material, such evacuation may prove demanding and it should be done by direct approach to prevent infection of any remaining material. It may even be necessary to leave the wound to heal by secondary intention.

Although complications of non-resorbable injectables have been reported, their occurrence rate remains unknown. In Switzerland, approximately 80 out of 5000 patients injected with such fillers (1.6%) were registered to show granulomas.<sup>18</sup> Thirteen of the cases we report herein were referred to us by one cosmetic practitioner. Currently, this practitioner treats approximately 1000 new patients with injectable fillers per year and he uses polyalkylimide 4% in half of these patients. Because he has been injecting this filler material over the past 5 years, the estimated occurrence rate of complications in his experienced hands appears to be at least one in every 192 patients. Still, the true occurrence rate is very likely to be higher as his annual patient load increased over these 5 years and because long-term complications occur only after a time lag of 2 to 3 years.<sup>18</sup> The latter is well known for other non-resorbable injectable fillers.<sup>9,13,17</sup> Moreover, some complications typically occurred after

additional invasive treatment subsequent to the polyalkylimide injections and the incidence may be far higher in this subgroup of patients. Because we do not know how many patients undergo such additional treatment, we cannot estimate the occurrence rate of complications among this subgroup.

Given the potentially disfiguring therapy needed to treat these complications, we warn against the use of such permanent fillers for cosmetic indications.<sup>4,9</sup> This is in line with the recommendations regarding non-resorbable injectable filler materials provided by the Federal Office of Public Health in Bern, Switzerland, together with the Swiss Society of Plastic, Reconstructive and Aesthetic Surgery, the Swiss Society of Dermatology and Venereology, and the Swiss Society of Aesthetic Medicine.<sup>19</sup> As polyalkylimide 4% may successfully fill a facial soft tissue deficit, it may have a place for severe reconstructive indications such as facial lipodystrophy.<sup>7,12</sup> Additional, or secondary, treatment in patients who previously had this non-resorbable filler material injected should be done under strict aseptic circumstances. Once infection or migration of the permanent filler has occurred, the therapeutic options are limited to surgical removal by direct approach.

## References

- Peters W. The chemical peel. *Ann Plast Surg* 1991;**26**: 564–71.
- Fulton Jr JE, Porumb S. Chemical peels: their place within the range of resurfacing techniques. *Am J Clin Dermatol* 2004;**5**:179–87.
- Lemperle G, Morhenn V, Charrier U. Human histology and persistence of various injectable filler substances for soft tissue augmentation. *Aesthetic Plast Surg* 2003;**27**:354–66.
- Maillard G-F. Medical alert: facial wrinkles – injectable filler materials. *Plast Reconstr Surg* 2005;**115**:337–8.
- Ascher B, Cerceau M, Baspeyras M, et al. Les compléments par l'acide hyaluronique – soft tissue filling with hyaluronic acid. *Ann Chir Plast Esthét* 2004;**49**:465–85.
- Lindqvist C, Tveten S, Eriksen Bondevik B, et al. A randomized, evaluator-blind, multicenter comparison of the efficacy and tolerability of Perlane versus Zyplast in the correction of nasolabial folds. *Plast Reconstr Surg* 2005;**155**:282–9.
- Pacini S, Ruggiero M, Morucci G, et al. Bio-alcamid: a novelty for reconstructive and cosmetic surgery. *Ital J Anat Embryol* 2002;**107**:209–14.
- Zarini E, Supino R, Pratesi G, et al. Biocompatibility and tissue interactions of a new filler material for medical use. *Plast Reconstr Surg* 2004;**114**:934–42.
- Rohrich RJ, Potter JK. Liquid injectable silicone: is there a role as a cosmetic soft-tissue filler? *Plast Reconstr Surg* 2004;**113**:1239–41.
- André P. Evaluation of the safety of a non-animal stabilized hyaluronic acid (NASHA-Q-Medical, Sweden) in European countries: a retrospective study from 1997 to 2001. *J Eur Acad Dermatol Venereol* 2004;**18**:422–5.
- Sidwell RU, Dhillon AP, Butler PEM, et al. Localized granulomatous reaction to a semi-permanent hyaluronic acid and acrylic hydrogel cosmetic filler. *Clin Exp Dermatol* 2004;**29**:630–2.
- Protopapa C, Sito G, Caporale D, et al. Bio-Alcamid™ in drug-induced lipodystrophy. *J Cosmet Laser Ther* 2003;**5**:226–30.
- Christensen L, Breiting V, Janssen M, et al. Adverse reactions to injectable soft tissue permanent fillers. *Aesthetic Plast Surg* 2005;**29**:34–48.
- Talmor M, Hoffman LA, LaTrenta GS. Facial atrophy in HIV-related fat redistribution syndrome: anatomic evaluation and surgical reconstruction. *Ann Plast Surg* 2002;**49**:11–8.
- Carr A, Law M. An objective lipodystrophy severity grading scale derived from the lipodystrophy case definition score. *J Acquir Immune Defic Syndr* 2003;**33**:571–6.
- von Eiff C, Jansen B, Kohlen W, et al. Infections associated with medical devices: pathogenesis, management and prophylaxis. *Drugs* 2005;**65**:179–214.
- Hage JJ, Kanhai RCJ, Oen AL, et al. The devastating outcome of massive subcutaneous injection of highly viscous fluids in male-to-female transsexuals. *Plast Reconstr Surg* 2001;**107**:734–41.
- Swissmedic. Nicht resorbierbare Injektionspräparate zur Faltenkorrektur – Stand 30.11.2002. *Swissmedic J* 2003;**2**:92–3. <[http://www.swissmedic.ch/files/pdf/02\\_2003.pdf](http://www.swissmedic.ch/files/pdf/02_2003.pdf)> [accessed February 12, 2005].
- Bundesamt für Gesundheit Bern, Switzerland. Bulletin 17-316: Empfehlungen betreffend nicht-resorbierbare Füllmaterialien zur Faltenkorrektur durch Unterspritzung. *Swissmedic J* 2002;**1**:245. <[http://www.swissmedic.ch/files/pdf/04\\_2002.pdf](http://www.swissmedic.ch/files/pdf/04_2002.pdf)> [accessed February 12, 2005].