

Zie ook <http://www.microneedle.com/main/clinicalstudy.html>

Micro Needling and Injecting Platelet Rich Plasma to Enhance Collagen Synthesis and Skin Tightening.

Author: Joseph F. Greco, PhD, PA/C

Abstract

The technique of medical micro needling has been shown to increase the remodeling of the skin by creating thousands of microscopic channels in the skin, to increase the formation of new tissue by activating the body's healing cascade. This author theorized, that micro needling platelet rich plasma (PRP) into the dermis would intensify the natural wound cascade because of the high concentration of the patients own growth factors. A method of collagen enhancement therapy utilizing a micro-needling roller to infuse PRP and other formulas into the skin, in combination with a Meso lift (non-surgical lift) of the neck and face to tighten and tone skin, is presented. Results reveal this method to be an effective alternative of collagen enhancement therapy (CET).

Introduction

The earliest form of micro needling, acupuncture, can trace its roots to the Chinese centuries ago. Nappage, a French skin rejuvenation technique used the past fifty years, is another form of micro needling where micro incisions are made into the skin placing a drop of vitamins, minerals and anti-oxidants to replace depleted cellular levels. In the 1990's (Orentreich, 1995) (1) advocated the "subcision" with a needle to treat wrinkles near the lip lines. In 1997, (Comrade, et al.) (2) reported that hypochromic facial scars were tattooed with a skin color pigment and 1 to 2 years later, even after the pigment was gone, it was replaced by actual melanin and the scars were improved in texture, appearance and color. After observing this, scars were tattooed without pigment with the idea that breaking down the scar collagen in this manner would cause realignment and stimulate melanogenesis.

Discussion

An obvious advantage with this procedure is the fact that the epidermis, the protective layer of the skin, is preserved. In his studies, (Fernandes, 2005) (3) promoted the fact that "we should never purposefully destroy the epidermis." The technique of medical micro needling has been shown to increase the remodeling of the skin by creating thousands of microscopic channels thru the skin, to increase the formation of new tissue by activating the body's wound healing cascade (hemostasis-inflammation-proliferation-tissue remodeling). The micro-channeling causes the release of growth factors that promote scar-less healing and the deposition of normal woven collagen rather than scar collagen.

There are various delivery systems in micro needling, but micro needling via a roller system, which creates literally thousands of channels thru the epidermis, appears to be most effective. The roller channeling method is safe, cost effective, and simple. Needle depth is pre set and below a 5mm roller MTS, Clinical Resolutions Labs, Inc.

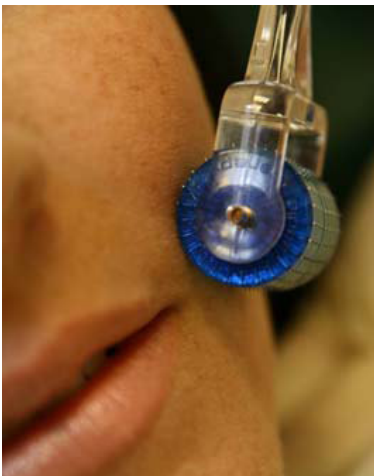

Fig 1

The comparative slides below Fig 2, (Control) demonstrated by (Schwartz, 2006) (4) shows new collagen and elastin formation Fig 3, (CIT side) 6 weeks after "dry" micro needling. Dry meaning, "no substance was used or infused into the skin". In this study, twenty blinded biopsies taken from 10 different patients from various parts of their body demonstrated an average increase in new fibers of 206%, one biopsy a 1000% increase was recorded.

Fig 2 (Before)

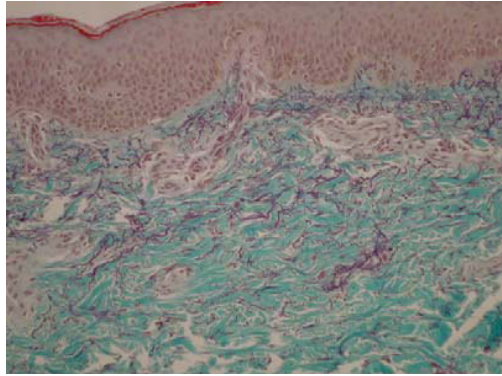
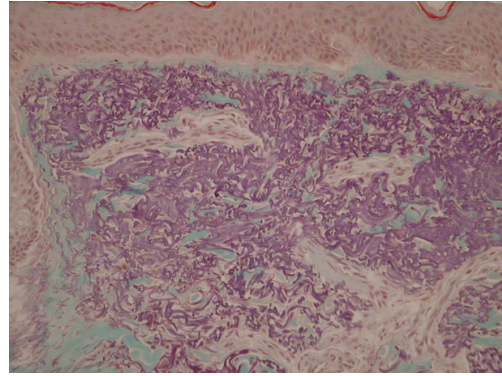


Fig 3 (After)



This study also evaluated the penetration forces and needle length. Interestingly, after evaluation of all the biopsies, new collagen fibers were only found at the corium not deeper than 0.5mm to 0.6 mm. Even though 1.5 mm needles were used, no new collagen fibers could be found in the sub dermal layer illustrating no benefit to using longer more invasive needles.

A second study by Korean Dermatologists (Kim, et al, 2006) (5) compared IPL (Elipsee, DDDD, Denmark) to micro needling (MTS roller TM Clinical Resolution, INC, USA) while evaluating collagen synthesis. Patients received three treatments at two week intervals (18 Control, 18 IPL, 18 MN). Micro needling (MN) demonstrated:

- 1) more skin thickness than IPL or control
- 2) histology (MT stain) more collagen fiber than IPL or control
- 3) and a higher collagen qualitative analysis via (ELISA, WB) than IPL or control.

If “dry” micro needling caused new collagen synthesis via the natural wound cascade, this author theorized, that micro needling platelet rich plasma PRP into the dermis would intensify the immune response because of the high concentration of the patients own growth factors.

Platelet derived growth factor PDGF is the evolutionary sentinel growth factor that initiates all wound healing. Platelet rich plasma (PRP) contains several growth factors, including platelet-derived growth factors (PDGF), transforming growth factor-beta 1 (TGF-beta 1) at high levels and vascular endothelial growth factor (VEGF). When platelets are activated growth factors are released which emit chemical signals to surrounding areas multiplying the growth factors thus causing a heighten “immune response”.

Platelet derived growth factors' main functions are to stimulate cell replication (mitogenesis) of healing capable stem cells. It also stimulates cell replication of endothelial cells. This will cause budding of new capillaries into the wound (angiogenesis), a fundamental part of all wound healing. In addition, PDGF seems to promote the migration of perivascular healing capable cells into a wound and to modulate the effects of other growth factors.

Growth Factors are essential for regulation the cellular events involved in wound healing by attracting cells to the wound, stimulating proliferation, and significantly influencing matrix deposition. (Declare, 1999) (6)

Fibroblasts are among the cells that are activated by TGF-beta. When a fibroblast is activated it will under go cell division and produce collagen. Collagen deposition is responsible for plumping the skin and reversing the visible signs of aging.

TGF-beta is extremely important because it affects most aspects of tissue wound repair, namely initiation and termination and also promotes differentiation and proliferation (Chio and Fucks, 1990) (7). PDGF improves dermal regeneration, acts locally to promote protein and collagen synthesis, causes endothelial migration or angiogenesis (Ross, 1987) (8) and induces the expression of TGF-beta (Pierce et al., 1989a) (9).

It was further established that wounds treated with PRP gel exhibited not only enhanced wound repair compared to controls, but also possess more organized collagen than controls tissues, without excessive disposition of connective tissue or scar formation (Carter, et al., 2002) (10).

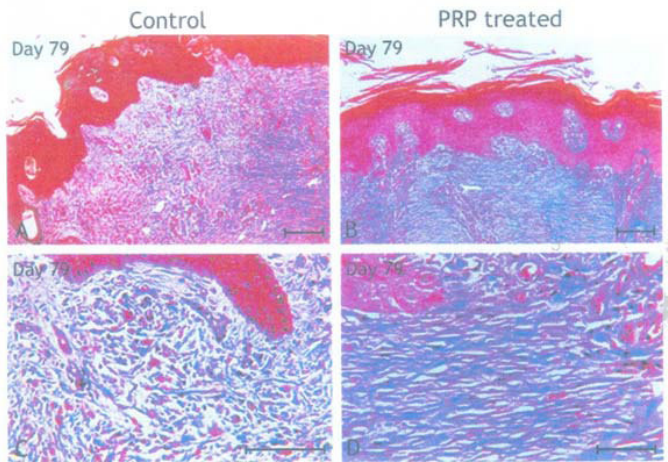


Fig 4

This equine study demonstrated biopsy wounds treated with PRP gel to be densely organized, tightly packed fiber bundles parallel to the overlying epidermis suggesting the dense collagen lattice had increased tensile strength in the repaired wound. (Fig 4, Lower right slide).

PRP is safe because it is obtained from the patients own blood via phlebotomy and avoids the risk of transmissible diseases such as HIV, Hepatitis B, C, or D, and other blood borne pathogens. Because it is used topically in and on top of a wound in a clotted fashion, it never re-enters the individual's circulation. It is therefore safe when clot accelerators such as bovine thrombin are used or when PRP is added to other materials such as bovine collagen, gel foam, PLA-PGLA constructs, etc.

Method

First, 50cc blood is drawn from the patient, centrifuged for 10 mins until the platelets, which carry the growth factors, are separated from the remaining blood. See Fig 5 and Fig 6 below (Blood Recovery Systems, Inc.)

Fig 5



Fig 6



Second, the patient undergoes microderabrasion to remove the stratum corneum in the treatment area, while the platelets are being separated, to prepare the skin surface for the PRP.

Third, the treatment area undergoes nappage, via medical micro needle therapy (Fig 7) below to produce microscopic channels thru the epidermis in order (1) to increase the penetration of the PRP into the dermis and (2) to initiate the immune response in the dermal layer.

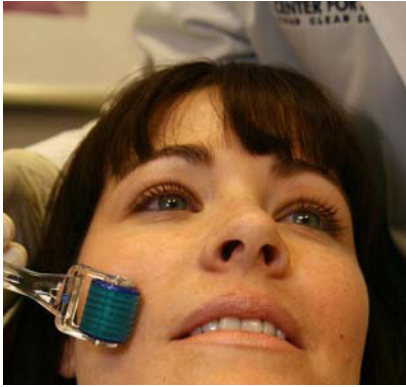

Fig 7

Fourth, the activated PRP or toning formula is then applied to the face and nappage is continued with the roller for the CET treatment only.

NOTE: The maximum effect of a Mesolift of the neck and face can be achieved at this point by injecting PRP and a skin toning formula. A Mesolift, or non-surgical skin tightening, utilizes micro injections of a variety of skin toning formulas and or a lipolytic formula to achieve a desired result. It is the synergistic effect of the toning formulas and the bodies “wound response”, caused by the needle that produces the desired effect. After the injections, a 0.5mm MTS roller is used on the treated areas to induce collagen synthesis.

Fig 8 illustrates the Meso lift Injection pattern and Fig 9 illustrates the patient immediately after the injections, note the erythema.

Fig 8

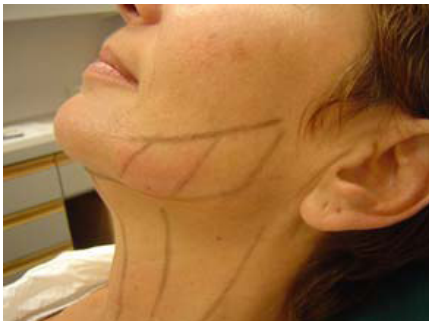
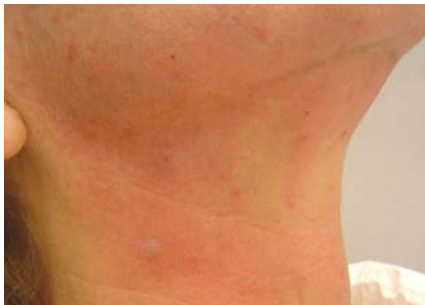
Fig 9



Fifth, freeze-dried collagen sheets (Reviva Labs, New Jersey) moistened with PRP, saline and or a toning formula, is applied to the area for 30 minutes (Fig 10). The collagen sheets hydrate the skin and infuse the PRP or toning formula into the micro channels. The channels close within an hour entrapping the PRP or toning formula beneath the epidermis. Note the contrast in Fig 11, immediately after the collagen sheets were removed, to Fig 9, prior to the application of the sheets.

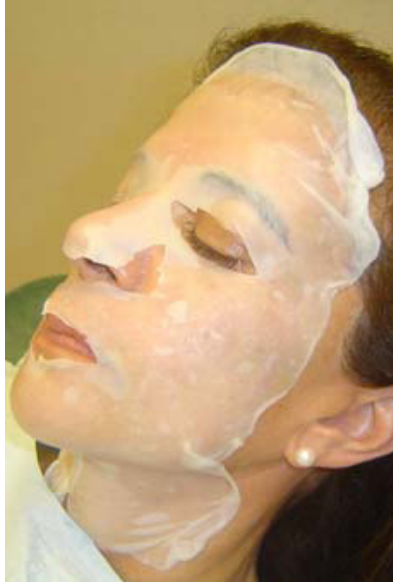

Fig 10

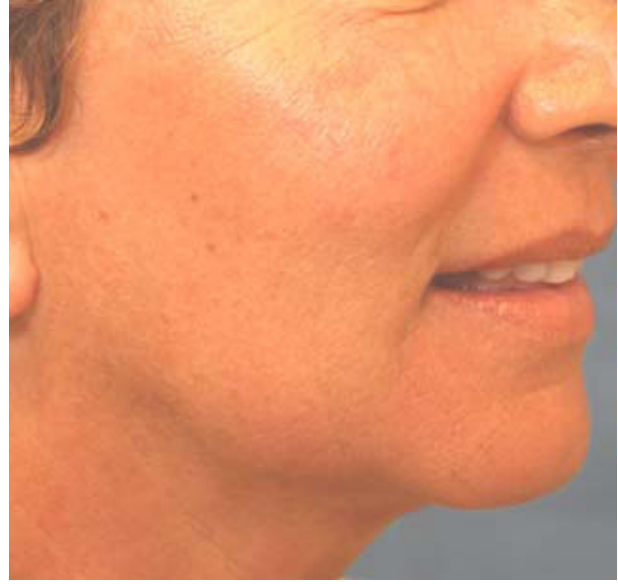

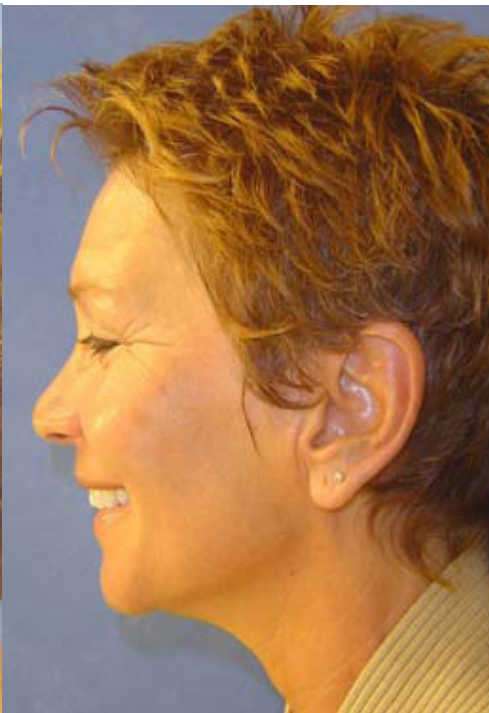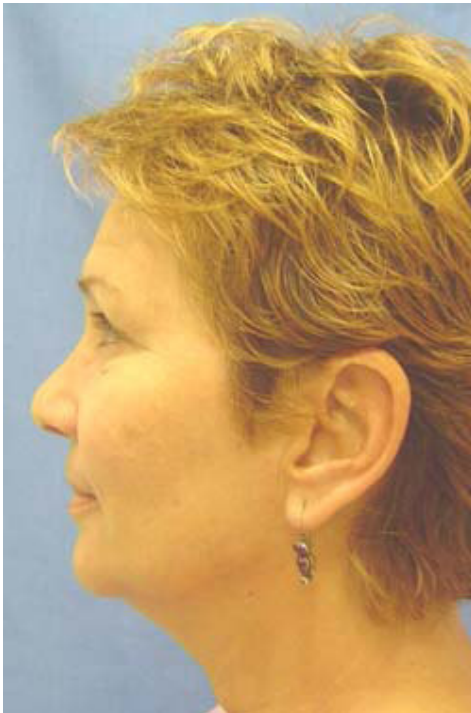Fig 11

While it is a rare complication, all patients are patch tested with a small moist piece of collagen on the patient's inner arm at the beginning of the procedure.

The patient in Fig 12 and Fig 13 below had two Meso lift treatments with CET one month apart. PRP was only used in the initial session. A toning formula and hyaluronic acid was infused in the second session along with CET on the face and neck. Note the tightening of her neck, along the mandible and the glow to her skin.

Fig 12 (Before)

Fig 13 (After)



The patient below in Fig 14 had two CET sessions. In the first procedure, PRP was infused and in the second procedure a toning formula was used along with hyaluronic acid. Note the changes in Fig 15 at eight weeks, notably the smoothing of the scarring in the cheek, above the eye and the increased tone of the skin.

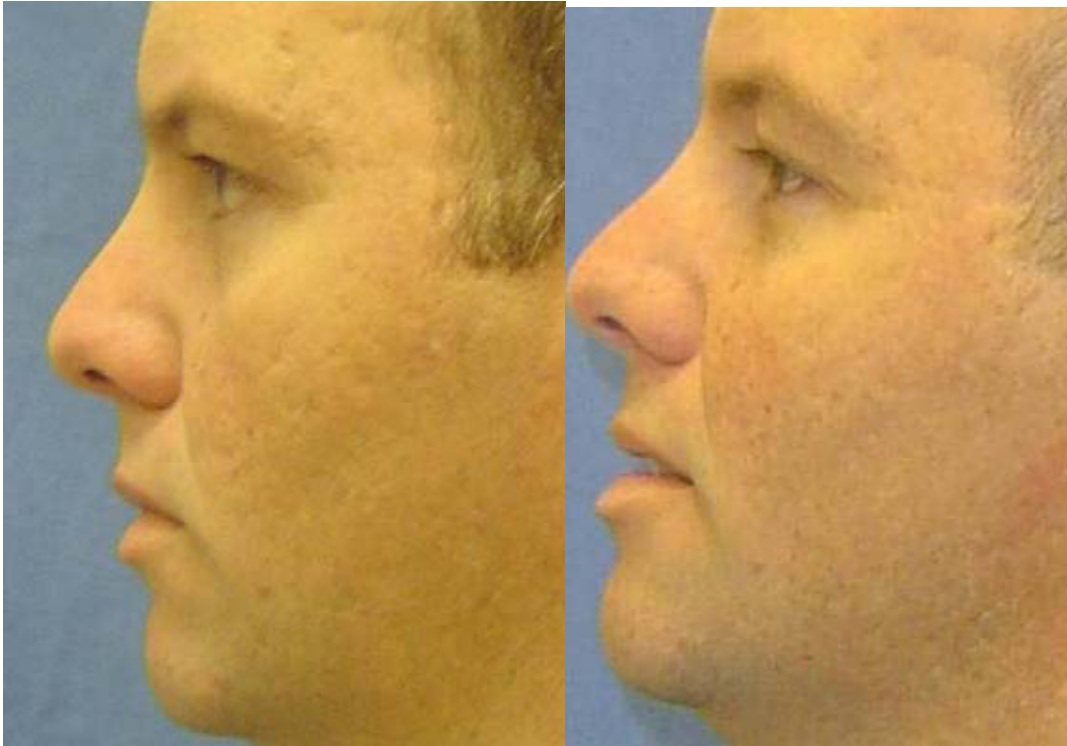

Fig 14 (Before)

Fig 15 (After eight weeks)

While it takes six weeks for new collagen synthesis and about six months for the full effect of the treatments, the common response by patients after the initial treatment is that their skin has a “glow” and females wear less make-up and feel more comfortable when they are not wearing make-up.

Conclusion

While it has been illustrated that “dry micro needling” will produce collagen synthesis in six weeks and micro needling with various toning formulas will enhance the skin remodeling, in our experience, patients undergoing “CET with PRP infusion” have noticeable results sooner and with fewer sessions than those patients undergoing CET alone or CET with toning formulas only.

The high concentration of growth factors entrapped in the micro channels after the epidermis closes, appear to accelerate wound healing cascade leading to skin remodeling.

Based on over fifteen years of clinical applications that platelet rich plasma has been utilized in wound repair, the collagen induction therapy studies cited and the patients presented above, this author believes the combination of PRP infusion with micro needling quantify the stimulation of new collagen synthesis and cell formation exactly where it is needed, right at the dermal layer.

Micro needling is an effective, versatile, cost effective delivery system that allows the physician to induce collagen synthesis by infusing any variety skin toning substances, including PRP. Collagen enhancement therapy is an effective adjunctive treatment combination with many other non-surgical protocols, like the ones presented, to tighten and tone skin, reduce acne scarring, stretch marks, fine lines, and to reduce the dimpling appearance of cellulite.

References

- 1- Orentreich DS, Orentreich N, Subcutaneous incision-less (subcision) surgery for the correction for depressed scars and wrinkles, *Dermatol Surg*, 1995; 21:543-549.
- 2- Camirand A. Douchet J, Needle Dermabrasion. *Aesthetic Plast Surg*.1997; 21:48-51.
- 3- Fernandes D Minimally invasive percutaneous collagen induction. *J Oral Maxillofac Surg Clin North Am*. 2005; 17:51-63.
- 4-Schwartz et al, 2006, internet paper. Abstract reflections about COLLAGEN-INDUCTION-THERAPY (CIT) A Hypothesis for the Mechanism of Action of Collagen Induction Therapy (CIT) using Micro-Needles; 1st edition February 2006. 2nd revision January 2007
- 5- Kim S.E., Ko D.S., and Lee A.Y., Moon H.S., Medical Conference Presentation, Dongguk University, 2005. Medical Science Lab of the Dept. of Dermatology at Eulji University School of Medicine and the Dept. of Dermatology, School of Medicine at Dongguk University.
- 6- Declair, V., 1999. The importance of growth factors in wound healing. *Ostomy Wound Manage*. 45, 64-68.
- 7- Choi, Y., Fuchs, E., 1990. TGF-beta and retinoic acid regulation of growth and modifiers of differentiation human epidermal cells. *Cell* 61, 791-809
- 8- Ross, R., 1986. Platelet-derived growth factor. *Am Rev. Med*. 38, 71-79.
- 9- Pierce, G.F., Mustoe, T.A., Lingelbach, J., Masakowski, V.R., Gramates, PP. Deuel, T.F., 1989a. Transforming growth factor B reverses the glucocorticoid-induced wound healing defect in rats: possible regulation in macrophages by platelet-derived growth factor. *Proc. Natl. Acad. Sci.*, 86, 2229-2233.
- 10- Carter, C.A., Jolly, D.G., Worden, C.E., Hendren, D.G., Kane, C.J.M., Plate-rich plasma gel promotes differentiation and regeneration during equine wound healing, *Experimental and Molecular Pathology*, 74, (2003), 244-255.